

# **Endoscopic versus microscopic stapedectomy; Advantage and outcome**

**Ayman A. Mohamdy, Bassem F. Mikhail, Mohammed A. Elsayed, ahmed Abood, Alaa M. Abdelsamie**

## **ABSTRACT**

**Object:** To evaluate the surgical outcomes of endoscopic stapedectomy, comparing the results with a conventional stapes surgery under microscopic approach.

**Methods:** This study was carried out in Otorhinolaryngology Head and Neck Surgery department of both Benha University Hospitals and Hearing & Speech Institute upon 30 patients divided into two groups, each consists of 15 patients, Group A underwent endoscopic stapedectomy, Group B underwent microscopic stapedectomy from June 2019 till March 2020 to evaluate the advantages of endoscopic stapedectomy in comparison to microscopic one.

**Results:** We reported that 14 patients (93.3%) of the endoscopic group showed improvement in hearing, while only one patient (6.7%) complained of recurrent hearing impairment at the 6<sup>th</sup> month follow up after lifting heavy object while hearing was very good at 1<sup>st</sup>, and 3<sup>rd</sup> months follow up. All patients (100%) of the microscopic group showed improvement in hearing at 1<sup>st</sup>, 3<sup>rd</sup> and 6<sup>th</sup> months post-operative with nearly closed ABG.

**Conclusion:** Endoscopic surgery is particularly suitable for stapedial disease. Endoscopic stapes surgery can be performed despite a curved and narrow external auditory canal and is minimally invasive, being characterized by little drilling and almost no postoperative pain.

## **Keywords:**

Endoscopic, Microscopic, Stapedectomy.

## **Introduction**

Today, the endoscope plays an important role in cholesteatoma surgery in some centers in the world; however, there are still very few papers in the literature discussing the possible benefits of stapes surgeries

with the use of the endoscope, especially those studies based on the exposure of the oval window niche and stapes visibility [1].

Although the operating microscope provides good illumination and magnification, it has important limitations, such as a line-of-sight view, which allows the surgeon to visualize only the structures directly ahead. The endoscope, however, offers the possibility of “looking around corners” by using optics with different angles [2].

One of the important steps in performing stapes surgeries under the microscope is to partially remove the bone wall of the most medial segment of the external acoustic meatus. This important step in this surgery enables a better exposure of the incus-stapes joint, the oval window niche, pyramidal eminence and other important structures in this procedure. Nonetheless, such step requires exposure, manipulation and, in some cases, irreversible trauma of the chorda tympani nerve in order to have the best visualization of the oval window niche. Another important point to be considered during stapes surgery under the microscope is the visualization of the stapes supra-structure. Most of the times, when using a transcanal approach under the microscope, the surgeon is unable to see the stapes anterior crus, forcing the surgeon do blindly fracture such structure [1].

Endoscopic stapedectomy has many advantages as equipment use is optimized, Image resolution is excellent. It can be used for documentation purposes, very portable can be used even in rural settings which may not have operating microscopes, useful in performing the surgery in patients with a short chorda tympani nerve, excessive removal of bony overhang need not be resorted to [3].

Endoscopic stapes surgery also has some disadvantages. Manipulation with one hand is problematic. However, bleeding during stapedectomy is limited and aspiration should be minimized after fenestration during stapes surgery, so there is little need to use an aspiration tube held by the left hand and surgery can be completed with the right hand alone, stereoscopic vision cannot be obtained because the monitor is two-dimensional [4].

### **Materials and Methods:**

A prospective randomized clinical study involved 30 patients attending to the outpatient clinic of departments of Otorhinolaryngology, Head and Neck Surgery department of both Benha University Hospitals and Hearing & Speech Institute, from June 2019 till March 2020.

Patients were randomly allocated into two groups, each consists of 15 patients, Group A underwent endoscopic stapedectomy, and Group B underwent microscopic stapedectomy. These patients selected as random sample by sealed envelop method.

The aim of this study is to evaluate the surgical outcomes of endoscopic stapes surgery, comparing the results with a conventional stapes surgery under microscopic approach.

Institutional ethical clearance was taken prior to conduction of this study. The patients were explained that there were chances of failure of this new technique. Patients not agreeing after explanation were not operated endoscopically and thus excluded from the study. An informed written consent was taken from all the patients who agreed to undergo operation by this new technique.

Hearing impairment (without any history of middle ear infection), normal otoscopic findings, pure tone audiometry showing conductive hearing

loss with an AB gap-30 dB, normal bone-conduction threshold at 500,1000, 1500 and 2000 Hertz (Hz), stapedius reflex absent, and normal temporal bone CT Scan were enrolled in our study (**table 1**).

Patients not fulfilling one of the inclusion criteria or requiring a revision surgery or surgery on the only hearing ear or patients not fit for general anesthesia or patients complaining of chronic diseases were excluded from the study.

<i>Site</i>	<i>Endoscopic</i> (n=15)	<i>Microscopic</i> (n=15)	$\chi^2$	<i>p</i>
<b><i>Laterality</i></b>				
<i>Unilateral</i>	4 (26.7%)	3 (20%)	.186	.666
<i>Bilateral</i>	11 (73.3%)	12 (80%)		
<b><i>Type of hearing loss</i></b>				
<i>Conductive</i>	13 (86.7%)	15 (100%)	1.034	.309
<i>Mixed</i>	2 (13.3%)	0 (0%)		
<b><i>Degree of hearing loss</i></b>				
<i>Mild</i>	7 (46.7%)	7 (46.7%)	---	1
<i>Moderate</i>	8 (53.3%)	8 (53.3%)		
<b><i>Tympanogram</i></b>				
<i>Type A</i>	4 (26.7%)	3 (20%)	.180	.671
<i>Type A.S</i>	11 (73.3%)	12 (80%)		
<b><i>Acoustic Reflex</i></b>				
<i>Absent</i>	15 (100%)	15 (100%)	---	---

**Table (1):** Audiological symptoms of the two studied groups.

### **Surgical procedure:**

There were no differences of the surgical procedures between the two groups. All patients were placed in the same position for conventional ear surgeries done under the microscope. The surgical procedures were performed under general anesthesia and endotracheal intubation and by the same staff member.

Application of local injection of ephedrine and saline (1/100000) in anterior and posterior meatal walls 10 minutes preoperatively. Incision was done by using suction-fenestrated round knife at 6 to 12 hours direction vertically and one horizontal incision posteriorly merged the previous vertical ones about 1-2 mm from the annulus with elevation of tympanometal flap. Releasing the chorda tympani nerve and repositioning it away from exposure and removal of bony overhang if necessary (**figure 1**). Confirmation of presence of all ossicles and exclusion of presence of ossicular disconnection, trauma or congenital malformation was done. Testing mobility of malleus, Incus and Stapes was done. A small, 0.6mm in diameter, stapedectomy hole was punched in the posterior portion of the stapes footplate, with a small 0.6mm tip micro perforator. The distance from the footplate to the long limb of the incus was measured. In all the cases we used Teflon prosthesis; 0.6mm in diameter and the length adjusted by measuring in each case which was made from the length measured between the footplate and the medial surface of the incus's long process.

The prosthesis was placed in this hole and fit along the long process of the incus subsequently (**figure 2**), the incudostapedial joint was removed using a pick, the stapedius tendon was severed, and the superstructure of the stapes was removed (**figure 3**). We avoided frequent suction, especially after opening the footplate, in order to avoid post-op complications, such as vertigo and cochlear damage. The malleus was

palpated in order to rule out head fixation and make sure the entire ossicular chain moves all the way to the prosthesis, (**Figure 3**). In order to seal the footplate, we used small pieces of fat plug, temporal fascia or sometime dry Gelfoam used, placed with the micro scissors. Following that, the tympanic-meatal flap was repositioned and we then inserted Gelfoam® dressing in the external acoustic meatus, without ointments or creams.

### **Parameters Investigated**

The parameters investigated were the operating time, extent of drilling at the posterosuperior part of the external auditory canal, postoperative hearing, intraoperative and postoperative complications, (postoperative pain and postoperative dizziness).

Hearing was assessed at 1<sup>st</sup>, 3<sup>rd</sup>, 6<sup>th</sup> month's post-operative in both groups.

As regard intraoperative and postoperative complications, the incidence of floating footplate, facial paralysis, and chorda tympani injury were compared between the two groups.

As regarding pain, each patient was questioned about the severity of postoperative pain at approximately 6 hours after surgery. The severity was recorded using three grades: almost no pain, mild pain requiring no analgesics, and pain requiring analgesics. The severity of postoperative dizziness was compared as well as the duration of dizziness (number of days).

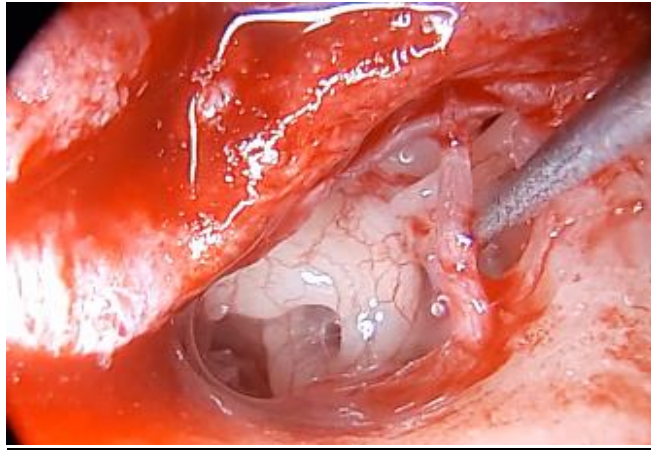


Figure 1. Endoscopic view showing releasing of chorda tympani nerve

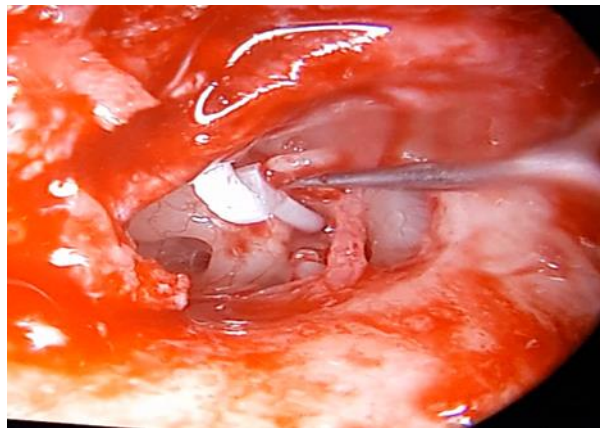


Figure 2. Endoscopic view of middle ear showing insertion of prosthesis.

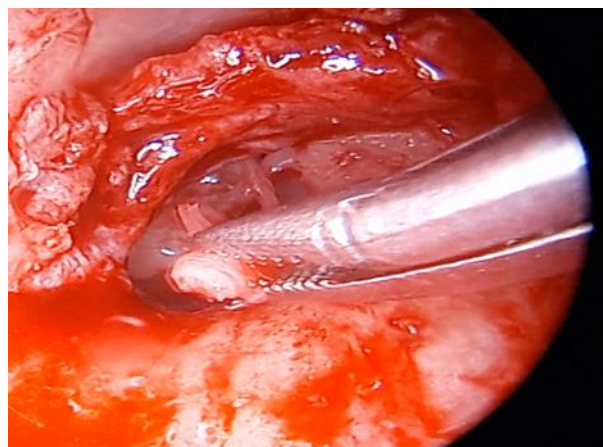


Figure 3. Endoscopic view of removal of stapes supra structure

## Results:

There were 30 patients in the study group between September 2017 and September 2018 divided into two groups, group A underwent endoscopic stapedectomy and group B underwent microscopic stapedectomy.

Demographic data of the studied subjects included 5 males and 10 females with mean age 35.87 years in the Endoscopic group & 6 males and 9 females with mean age 35.73 years in the Microscopic group (Table 2).

<i>Variable</i>		<i>Endoscopic</i> ( <i>n=15</i> )	<i>Microscopic</i> ( <i>n=15</i> )	<i>t / <math>\chi^2</math></i>	<i>P</i>
<i>Age (years)</i> <i>Mean <math>\pm</math> SD</i>		35.87 $\pm$ 7.56	35.73 $\pm$ 6.76	.051	.960
<i>Sex</i>	<i>Male</i>	5 (33.3%)	6 (40%)	0.144	.705
	<i>Female</i>	10 (66.7%)	9 (60%)		

**Table (2):** Demographic data distribution of the two studied groups

When the operating time was compared between the endoscopic group (15 ears), and the microscopic group (15 ears) the mean operating time was 56.33  $\pm$  7.89 and 56.67  $\pm$  7.94 minutes, respectively, showing no significant difference between the two groups (Table 3).

we evaluated hearing level subjectively and objectively at 1<sup>st</sup>, 3<sup>rd</sup> and 6<sup>th</sup> months post-operative for both groups, Better improvement defined as more than 10 db gain, Worse defined as more than 10 db loss and Equal (unchanged) defined as + or - 10 d b. We found that 14 patients (93.3%) of the endoscopic group showed improvement in hearing, while only one



patient (6.7%) complained of recurrent hearing impairment at the 6<sup>th</sup> month follow up after lifting heavy object while hearing was very good at 1<sup>st</sup> and 3<sup>rd</sup> months follow up. All patients (100%) of the microscopic group showed improvement in hearing at 1<sup>st</sup>, 3<sup>rd</sup> and 6<sup>th</sup> month's post-operative with nearly closed ABG (**Table 4**).

	<i>Endoscopic</i> (n=15)	<i>Microscopic</i> (n=15)	<i>t / <math>\chi^2</math></i>	<i>p</i>
<b><i>Operative time</i></b> Mean $\pm$ SD Median (range)	56.33 $\pm$ 7.89	56.67 $\pm$ 7.94	.115	.909
<b><i>Incidents</i></b>				
<i>Bony overhang curettage</i>	6 (40%)	15 (100%)	<b>12.85</b>	<b>&lt;0.001</b>
<i>Stapes fixation</i>	15 (100%)	15 (100%)	---	1
<i>Chorda Tympani N. injury</i>	0 (0%)	0 (0%)	---	1
<i>Perilymphatic gusher</i>	0 (0%)	0 (0%)	---	1
<i>Footplate and Oval Window injury</i>	0 (0%)	0 (0%)	---	1

**Table (3):** Operative timing and incidents of the two studied groups

<i>Site</i>	<i>Endoscopic</i> (n=15)	<i>Microscopic</i> (n=15)	<i><math>\chi^2</math></i>	<i>p</i>
<b><i>Hearing evaluation (subjective)</i></b>				
<i>Improving</i>	14 (93.3%)	15 (100%)	1.421	.233
<i>Not Improved</i>	1 (6.7%)	0 (0%)		
<b><i>Hearing evaluation (objective)</i></b>				
<i>Improving</i>	14 (93.3%)	15 (100%)	1.421	.233
<i>Not Improved</i>	1 (6.7%)	0 (0%)		

**Table (4):** Postoperative outcome of the two studied groups.

Only one case of the endoscopic group had late facial paralysis (10 days) after the surgery and he didn't have facial canal dehiscence and we didn't manipulate the facial nerve during the surgery, it showed complete healing 1 month after later. Also, none of the patients developed postoperative dysgeusia due to chorda tympani injury. In the microscopic group the chorda tympani was not severed in any of the patients. However, transient abnormal taste sensation that was presumably due to intraoperative chorda tympani traction occurred in four of the 15 patients.

The duration of dizziness after endoscopic surgery was 1 day (the day of surgery) in 14 patients (93.3%) and 2 days (until the next day) in 1 patient (6.7%). It was not 3 days or more in any patient. Yet the duration of dizziness after microscopic surgery was 1 day in 12 patients (80%), 2 days in 2 patients (13.3%), and 3 days in 1 patient (6.7%) (**Table 5**).

As regards tinnitus, We didn't consider the tinnitus that happened on the 1<sup>st</sup> week post-operatively as a complication, because it happens approximately in all ear operations for a while, we evaluated tinnitus 1 month post-operatively , We found that only 2 patients (16.66 %) of the endoscopic group suffered from tinnitus in the operated ear in quiet atmosphere, By reviewing the pre and post audiogram we noticed both of them had SNHL on high frequency which may be the cause of this tinnitus for that reason we didn't consider that tinnitus occurred as a complication of endoscopic ear surgery (**Table 5**) .

12 patients (80%) of the endoscopic group had almost no pain post-operative while 3 patients (20%) of the same group had mild pain which required analgesics, yet 9 patients of the microscopic group suffered from irritating pain which required strong analgesics while 6 patients (40%) suffered no pain (**Table 5**).

<i>Site</i>	<i>Endoscopic</i> (n=15)	<i>Microscopic</i> (n=15)	$\chi^2$	<i>p</i>
<b><i>Tinnitus</i></b>				
<i>Present</i>	2 (13.3%)	0 (0%)	2.916	.088
<i>Absent</i>	13 (86.7%)	15 (100%)		
<b><i>Dizziness</i></b>				
<i>Present for a day</i>	14 (93.3%)	12 (80%)	1.487	.475
<i>Present for 2 days</i>	1 (6.7%)	2 (13.3%)		
<i>More than 2 days</i>	0 (0%)	1 (6.7%)		
<b><i>Pain</i></b>				
<i>No pain</i>	12 (80%)	6 (40%)	<b>5.178</b>	<b>.023</b>
<i>Mild pain</i>	3 (20%)	9 (60%)		

**Table (5):** Post-operative complications of the two studied groups.

## **Discussion:**

Since the introduction of stapes surgery by Shea in 1956, numerous modifications of the classical stapes operation have been described in medical literature with most of them being microscopic surgeries [5].

The scope of endoscopes in middle ear surgery is already being explored. Multiple papers, mostly based on anatomy, validate the plausible advantages of endoscopes in ear surgeries. These papers mostly emphasize the superior visualization of structures and recesses. However, most of the endoscopic ear surgery studies focus on infective ear diseases and cholesteatoma surgery, and the available literature about the role of endoscopes in stapes surgery are not so extensive [4].

First endoscopic stapedectomy procedure was published by Poe in 2000 and several papers were published since that time. These early publications have promising results. In this study, we tried to compare the surgical outcomes of endoscopic stapedectomy with a conventional stapes surgery under microscopic approach.

Our study concluded that there was no significant difference in Postoperative hearing outcome between the two groups. Comparison of the operating time showed no difference between endoscopic surgery and conventional surgery under the operating microscope.

In the endoscopic surgery group, postoperative dizziness did not persist for 3 days or more in any of the patients like what happen in microscopic group and was mild in all patients. This was presumably because the procedure for the fenestration of the stapedial footplate was gentler and reduced manipulation of the stapes footplate due to better visualization.

As regard to tinnitus, we evaluated tinnitus 1 month post-operatively as all ear operations can cause early post-operative tinnitus. We found that there was no statistical significant difference between two groups.

Also, none of the patients in endoscopic group developed postoperative dysgeusia due to chorda tympani injury but in microscopic transient abnormal taste sensation occurred in 4 patients (26.7 %) mostly due to intraoperative chorda tympani traction. With endoscopic surgery there are no blind spots, even if there is an overhanging posterior wall of the external auditory canal, and the chorda tympani can easily be identified. Therefore, endoscopic stapes surgery may be superior for surgical intervention on the chorda tympani.

These results coincide with *Koukkoullis et al. [6]* who showed that the hearing outcomes of the endoscopic approach are similar to those of the microscope. Endoscopically operated patients would suffer less with postoperative dizziness but without statistical significant difference between two groups. Also reported that there is no significant difference in operating time with a significant heterogeneity is seen in there results.

Results also agree with **Kojima et al. [4]** who they reported that there were no differences of operating time or postoperative hearing between the endoscopic and microscopic groups. There was very little postoperative pain in the endoscopic group. Postoperative dizziness was mild in all patients who underwent endoscopic surgery. The chorda tympani was preserved in all patients, and there were no cases of dysgeusia. Therefore, endoscopic stapes surgery may be superior for surgical intervention on the chorda tympani. They concluded that endoscopic surgery is particularly suitable for stapedial disease.

However, *Sproat et al. [7]* concluded that Air-bone gap closure and patient complications did not vary significantly between endoscopic and non-endoscopic groups in this study of 34 endoscopic procedures. There is a requirement for further studies with larger sample sizes and longer follow-up periods to fully gauge the safety and effectiveness of this technique.

Also, we found that there was significant lower post-operative pain in endoscopic group due to less drilling of the external auricular canal and gentle manipulation of foot plate. This result not coincides with **Koukkoullis et al. [6]** who reported that there was no statistical difference in post-operative pain between two groups. However, pain is less in endoscopic group.

Only one case of the endoscopic group had late facial paralysis (10 days) after the surgery and he didn't have facial canal dehiscence and we didn't manipulate the facial nerve during the surgery, it showed complete healing 1 month after later. The mechanism of the neural dysfunction is not readily defined. It may be due to reactivation of dormant viruses or traction of the chorda tympani nerve with a resultant retrograde facial nerve edema.

**Sarkar et al. [8]** published their results of endoscopic stapedectomy surgeries in 2013. They have 32 patients. They reported that they shifted to microscopic surgery in 2 patients due to perilymph gusher.

This is a good example for showing the limitation of endoscopic stapedectomy surgery. Every surgeon should recognize and keep in mind that; endoscope does not replace the need for microscope in surgery. Therefore microscope should be available in the operating room in every endoscopic ear surgery. Surgeons should not hesitate to shift the microscopic surgery when needed.

## **Conclusion and recommendations**

Endoscopic surgery is particularly suitable for stapedial disease and good alternative to microscopic surgery. As endoscopic stapes surgery give similar audiological success, can be performed despite a curved and narrow external auditory canal and is minimally invasive, being characterized by little drilling and almost no postoperative pain with lower risk of chorda tympani injury and postoperative taste disturbance. It also suitable for education; the surgical anatomy can be easily understood and both the surgeon and assistants can observe procedures on the same monitor.

We recommend performing endoscopic stapedectomy only by experienced surgeons because the operation has to be done one-handed and because stereoscopic vision is unavailable. In addition, we recommend further studies with larger sample sizes and longer follow-up periods to fully gauge the safety and effectiveness of this technique.

## References

1. Nogueira Júnior JF, Martins MJ, Aguiar CV, Pinheiro AI. Fully endoscopic stapes surgery (stapedotomy): technique and preliminary results. *Braz J Otorhinolaryngol.* 2011; 77(6): p.721-727.
2. Marchioni D, Molteni G, Presutti L. Endoscopic Anatomy of the Middle Ear. *Indian J Otolaryngol Head Neck Surg.* 2011; 63, p.101–113.
3. Balasubramanian T, Venkatesan U. Endoscopic Otology A supplement. *Otolaryngology.* 2012; 2:p.1–25.
4. Kojima H, Komori M, Chikazawa S, et al. Comparison between endoscopic and microscopic stapes surgery. *Laryngoscope.* 2014; 124(1): p. 266-271.
5. Kisilevsky VE, Bailie NA & Halik JJ (2010) Modified laser-assisted stapedotomy. *Laryngoscope* 120, 276– 279
6. Koukkoullis A, Tóth I, Gede N, Szakács Z, Hegyi P, Varga G, Révész P. Endoscopic versus microscopic stapes surgery outcomes: A meta-analysis and systematic review. *The Laryngoscope,* 2020; 130(8), 2019-2027.
7. Sproat R, Yiannakis C, Iyer A. Endoscopic stapes surgery: a comparison with microscopic surgery. *Otology & Neurotology,* 2017; 38(5), 662-666.

8. Sarkar S, Banerjee S, Chakravarty S, Singh R, Sikder B, Bera SP. Endoscopic stapes surgery: our experience in thirty two patients. Clin Otolaryngol. 2013; 38(2):p.157-160.